vol 8 issue 1 | january 2002

imaging update

LOW BACK PAIN

Queensland Diagnostic Imaging

THERAPEUTIC PERCUTANEOUS PROCEDURES FOR LOW BACK PAIN

Rationale & protocols for facet blocks-medial branch blocks & percutaneous radiofrequency neurotomy.

1. FACET BLOCKS

(Facet Joints = Zygapophyseal Joints = Z joints)

Intra-articular facet blocks

If the clinical history and examination is indicative of facet joint related pathology, intra-articular blocks can be utilised as a diagnostic test. Although intra-articular facet blocks are non-specific in their action, the intra-articular injections of Marcain and Celestone Chronodose have a quite definite place in the temporary treatment of facet related low back pain and neck pain. Occasionally one injection is all that is required to relieve the symptoms. A most important consideration is, however, that they are non-specific.

On most occasions, intra-articular injections do not provide lasting relief and, in addition, intra-articular injections of steroid are not target specific and therefore lack specificity. The capacity of a facet joint is generally quite small. Overinjecting the joint simply allows leakage through perforations in the capsule medially into the epidural space and laterally into the peri-articular tissues. These injections do not specifically target the facet joint.

On the other hand, if they relieve the patient's symptoms, they obviously have a place in the temporary treatment of low back pain in selected patients.

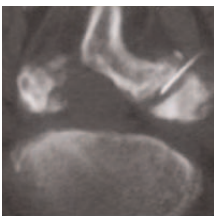

CT guidance provides precision in intra-articular blocks.

Indications

Intra-articular facet injections, with long acting local anaesthetic and cortisone are indicated:

a) to confirm a clinical impression of facet related low back pain

b) if an initial diagnostic block is the aim prior to planning further therapy

c) or if the patient is going to be treated conservatively anyway and not with radiofrequency neurotomy.

2. MEDIAL BRANCH BLOCKS

The medial branch of the posterior primary ramus mediates pain from the facet joints. *Each joint is innervated by the medial branch above and below the joint.* Small branches of this nerve continue onwards into the Multifidus muscle in the back but do not continue onwards to innervate the skin. Blocking the medial branch is a diagnostic procedure designed to test specifically whether or not these nerves mediate the patient's pain symptoms. Multifidus has multiple nerve supplies and no chronic pain producing pathology is known to effect the Multifidus. Hence medial branch blocks are target-specific and are the best known method of determining whether or not the patient's pain is originating in the facet joints.

They are a specific test for the diagnosis of lumbar facet joint pain.

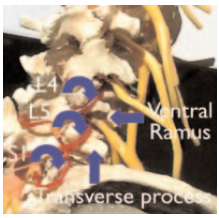

Location of the medial branches.

Indications

Medial branch blocks are indicated for patients with low back pain suggestive of facet joint pain. It is generally accepted that the only validated treatment for pain mediated by the lumbar medial branches, is percutaneous radiofrequency neurotomy. If this treatment is available, medial branch blocks are essential prior to deciding whether or not this type of treatment is appropriate.

Medial branch blocks are indicated as follows:

(a) For diagnostic purposes to establish the source of pain.

(b) To establish whether the patient is likely to respond positively to radiofrequency neurotomy.

Medial branch blocks are not appropriate in acute back pain.

Medial branch blocks are easily performed under radiological guidance. If a positive response is obtained, it can be logically

followed by radiofrequency neurotomy. Their primary role is a diagnostic one, to test whether or not the patient's pain is eliminated by anaesthetising the medial branch.

Precise radiographic localisation prior to electrode placement.

Response

a) **Negative response** - There is no pain relief or very little pain relief. This indicates that the pain or most of the pain is originating from a source other than the facet joints.

b) **Positive response** - If the pain is eliminated by medial branch bocks, it is good evidence that that the pain is originating in the facet joints.

False positive results

There are many sources of low back pain and the facet joints are simply one of these. Some patients may have several sources of pain and may have bilateral pain or they may have pain from several facet joints. For these reasons, medial branch blocks may only relieve part of the patient's symptomatology. In most cases complete relief of pain is not achieved. It is important that the patient is aware that complete relief of pain is not the object of the exercise. The procedure is desired to achieve a significant reduction in the degree of pain in the area targeted.

A true positive result is the complete relief of pain in the region targeted and this gives good predictive evidence for a positive and prolonged response to percutaneous radiofrequency neurotomy.

Injecting too many regions simultaneously is counterproductive in deciding which level or levels are producing the symptoms.

False negative blocks

a) Occasionally, the injection is inadvertently made into a vein and becomes intravenous and not local.

b) The patient is unable to discriminate between the pain that has been eliminated and persisting pain from other causes.

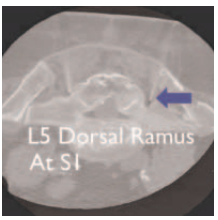

Fused or grossly arthritic joints preclude an intra-articular approach. The needle tips are shown in the correct position for MBBs at S1.

Control Blocks

Control blocks utilise local anaesthetic agents with differing durations of action. A true positive response to these differing anaesthetic agents would be a duration of pain relief relating directly to the type of anaesthetic used. From a practical point of view however this is not entirely necessary.

A positive response on two consecutive procedures using Marcain alone is very strong evidence that the patient will respond positively to radiofrequency neurotomy.

In the event of a weakly positive or negative response, radiofrequency neurotomy is not indicated.

Some difficulty is sometimes experienced in the interpretation of results from some patients who are overly enthusiastic to respond positively because they are so keen to have the radiofrequency treatment. They sometimes exaggerate their response to the blocks. Pressure is sometimes brought to bear by the referring doctor to proceed with radiofrequency without adhering strictly with the work-up protocol usually because they are equally keen to obtain relief of pain for their patient.

The failure to confirm a diagnosis of facet related back pain with satisfactory medial branch blocks can only result in high rates of treatment failures, together with wasted resources and, eventually may contribute to bringing disrepute to the procedure of radiofrequency treatment.

3. PERCUTANEOUS RADIOFREQUENCY NEUROTOMY

Protocol for the assessment for suitability for Percutaneous Radiofrequency Neurotomy (PRFN)

The standard RF machine used in RF neurotomies.

It is helpful for us to have a fairly clear understanding of the level or levels that are suspected clinically by the referring physician and whether there is unilateral or bilateral pain so that adequate time can be scheduled for the procedure at the time of the booking.

Stage 1

Medial branch blocks in the region under review using a small dose of long acting local anaesthetic. The results are assessed within 6 hours.

Stage 2

Repeat medial branch blocks to exclude false positive and false negative results. These can be performed with an anaesthetic of differing duration of action if thought necessary in some patients.

Stage 3

Percutaneous Radiofrequency Neurotomy. This follows if there has been satisfactory evidence of a positive response to the medial branch blocks.

These stages can be scheduled as close together as consecutive days but from a practical point of view they tend to be scheduled approximately one week apart.

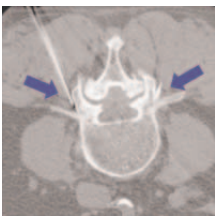

Electrode placement for RF neurotomies.

Complications

These are unlikely and are few in numbers.

a) As with any interventional procedure, the possibility of infection cannot be entirely eliminated. However a good aseptic technique will make this most unlikely.

b) Occasionally some local anaesthetic "leaks" on to the very closely adjacent Ventral primary ramus resulting in a temporary peri-radicular block and consequent leg weakness which generally lasts a few hours. This may occur not only with the medial branch blocks but also when the local anaesthetic is injected prior to PRFN. It is quite temporary.

c) Partial Neurotomy of the adjacent ventral ramus. This should not occur if the correct technique is adhered to and the patient is fully responsive. This is a good reason to avoid sedation and general anaesthesia. Prior to PRFN, the patient undergoes a test stimulation, which is designed to determine the correct placement of the electrode and eliminate this possibility. In addition, CT guidance gives accurate visualisation of the position of the electrode prior to neurotomy.

Expected results

a) Intra-articular blocks generally speaking, do not have a prolonged action although occasionally patients experience several months of relief. The procedure is designed as a diagnostic test and therefore, the therapeutic effect is unpredictable.

b) Medial branch blocks with local anaesthetic will have an effect for 4 to 6 hours.

c) PRFN will have an effect for several months, sometimes for well over a year in the region targeted.

HIC REQUIREMENTS

The HIC guidelines are quite clear. In order for the patient to receive a rebate, there must be separate request forms for each stage of the procedure. This means three (3) request forms. Two of these are for MBBs and the third is for the Radiofrequency should the results of stages 1 & 2 be appropriately positive.

WHERE ARE THESE PROCEDURES PERFORMED?

Currently PRFN is performed at

- QDI St. Andrew's Hospital, Wickham Terrace, Brisbane. (ph) 3839 5433
- QDI Sunshine Central, Kawana. (ph) 5478 4277
- Allamanda Private Hospital, Southport. (ph) 5532 7966

Russell S. Ferguson. FRANZCR. FRCR.
email: fergusonr@qdixray.com.au

Queensland Diagnostic Imaging

www.qdixray.com.au

QDI News

Privately owned, clinically independent.

Committed to delivering
the best technology, levels of service,
faster reporting times,
and services sensitive to the
needs of our patients and doctors.

WOMEN'S IMAGING CENTRES - WIC

QDI is further expanding its WIC facilities in Brisbane and the Sunshine Coast by opening new purpose-built sites at Indooroopilly and Kawana.

These will add to centres already established at North West Hospital and Strathpine.

WIC offers women patients a greatly improved level of screening and diagnostic examination in:

- Mammography
- BMD
- Breast Ultrasound
- FNA / Core Biopsy

Onsite QDI Radiologists will provide a high level of patient care, in separate and specially designed facilities. All Doctors and staff are trained and fully accredited.

Service to patients will be by appointment only. An appointment is necessary to ensure a complete examination is carried out.

From January 2002, Women's Imaging Centres will operate at:

- Indooroopilly
- Kawana, Sunshine Coast
- Strathpine
- North West Hospital

ELECTRONIC REPORTS TO DOCTORS

Only QDI is able to offer Doctors in South East Queensland a secure and proven electronic reporting system that follows the same methodology successfully operating for pathology reporting.

Referring Doctors are able to receive encrypted patient results via the internet.

The benefits of using the QDI system are:

- the software is extremely easy to install
- one click on the QDI icon delivers all the patient results
- easy access using popular clinical programs (Medical Director, MSS)
- automatic scheduling for set interval downloading
- no need to scan radiology reports
- patient report available immediately after examination

QDI will install the software on the surgery system and train staff in its use free of charge. Each surgery can be provided with a personalised encryption key to secure access.

An Electronic Reports Kit is available for each surgery by contacting Jason Chandler, QDI Liaison Officer, on mobile 0403 469 716.

QDI CORINDA OPENS IN DECEMBER

On Monday 17 December, 2001, QDI will relocate its practice from Sherwood to Corinda to allow our Sherwood site to immediately undergo a major commercial redevelopment by the owners.

QDI Corinda is at 667 Oxley Road, Corinda, right next door to the Corinda Specialist Centre. A number of convenient transport options to Corinda are available for patients:

- By car - free parking on site
- By train - via Corinda station 100 metres away
- By bus - Cnr Oxley Rd & Hassall St Corinda outbound, right opposite QDI

QDI Corinda will offer patients an expanded range of radiology services:

- Radiologist on site - immediate reporting available
- OPG - reported by Dr Paul Monsour, Oral Radiologist
- Ultrasound
- General X-ray

Enquiries should be directed in the first instance to **QDI Information Officer**
p. 3839 4244 f. 3831 0276 e. qdi@qdixray.com.au

GPO box 2762, Brisbane 4001

www.qdixray.com.au

Queensland
Diagnostic Imaging